



**PATIENT**  
Ronnie Mac Hawkes

**SPECIES**  
Feline

**BREED**  
DSH

**SEX**  
Male Neutered

**AGE**  
7 years

**WEIGHT**  
12.69lbs

**INTERPRETED BY**  
Maggie Machen  
Lamy, DVM  
DACVIM (Cardiology)

**IMAGING PERFORMED BY**  
Pamela Harrigan,  
RDCS

**HOSPITAL NAME**  
Mass Veterinary Services

**REFERRING VET**  
Dr. Masloski

**INVOICE**  
25398

**DATE**  
7/19/22

**PRESENTING CLINICAL SIGNS**

History: Ronnie is referred for a heart murmur noted in January. He has been premedicated with gabapentin this morning. Good appetite and normal activity level. Exclusively indoors. On exam: gallop noted with increased heart rate, grade II/VI parasternal murmur, PSS, lung fields clear, compressible thorax. BP: 110mmHg x 5. \*Sedated with propofol for study.

**ECHOCARDIOGRAM FINDINGS**

2D, m-mode, color flow and Doppler imaging is available.

**Left ventricle:** The LV diameter is normal with adequate myocardial function. The LV wall dimensions are borderline. There is mild fibrosis of the endocardium. The endocardium appears mildly remodeled. The papillary muscles appear hyperechoic and normal in dimension.

**Left atrium:** The left atrium is normal. No obvious smoke or thrombi seen.

**Mitral valve:** The mitral valve is normal in structure and mobility. No obvious systolic anterior motion is seen. No MR.

**Aortic valve/aorta:** The aortic valve is normal in morphology and mobility. Normal aortic outflow velocity; laminar flow. No aortic insufficiency.

**Right ventricle:** Normal right ventricular diameter and morphology indicating no overt evidence of pulmonary arterial hypertension.

**Right atrium:** The right atrium is normal in dimension.

**Tricuspid valve:** The tricuspid valve appears normal with no tricuspid regurgitation.

**Pulmonic valve/pulmonary artery:** The pulmonic valve is normal in morphology and mobility. No pulmonic insufficiency. Normal RVOT velocity; laminar flow.

**Pericardium/other:** No pericardial or pleural effusion noted. No obvious cardiac masses.

**Heart rhythm:** ECG reveals a sinus rhythm with an average HR of 150bpm.

**2-Dimensional Measurements**

Ao diam (cm)	0.9
LA diam (cm)	1.2
LA:Ao (Swe)	1.3
IVS thickness (cm)	0.55
LVID diastole (cm)	1.3
PW thickness (cm)	0.55
LVID systole (cm)	0.6
FS (%)	54

**Doppler Measurements**

PV Vmax (m/s)	0.6
AoV Vmax (m/s)	0.8
MR Vmax (m/s)	NA
TR Vmax (m/s)	NA
TR PG (mmHg)	NA

**INTERPRETATION OF THE FINDINGS**

Overtly normal cardiac structure and function are identified. The LV wall thickness is borderline, which may be a normal variant or may reflect early hypertrophic changes. Follow up is advised. Mild remodeling fibrosis of the left ventricular wall is noted, which is likely a normal variant. No significant valve leaks are noted, and flow through the great vessels is normal in velocity. No definitive cause is identified for the murmur in this study (likely due to sedation).

Prognosis is open.



**PATIENT**

Ronnie Mac Hawkes

**SPECIES**

Feline

**BREED**

DSH

**SEX**

Male Neutered

**AGE**

7 years

**WEIGHT**

12.69lbs

**INTERPRETED BY**

Maggie Machen Lamy, DVM  
DACVIM (Cardiology)

**IMAGING PERFORMED BY**

Pamela Harrigan, RDCS

**HOSPITAL NAME**

Mass Veterinary Services

**REFERRING VET**

Dr. Masloski

**INVOICE**

25398

**DATE**

7/19/22

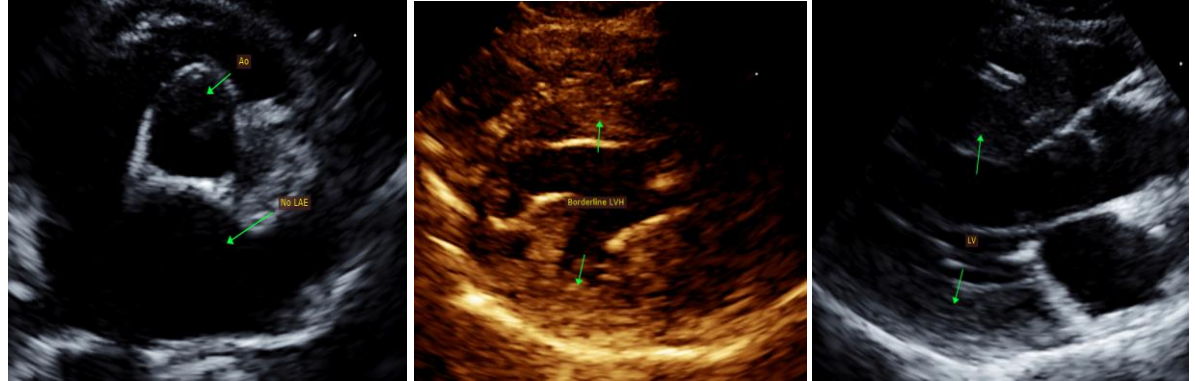
**RECOMMENDATIONS**

- Given these findings, no medications are indicated.
- No cardiac contraindication for general anesthesia. Should fluid or steroid therapy be indicated in the future, any cat should be monitored for intolerance (changes in RR/RE).
- Monitor at home for signs of cardiac compromise, including respiratory changes and/or signs of a blood clot event (paralysis, neurologic changes).

**PLAN**

- Recommend recheck echocardiogram in 6-12 months to assess for any progressive issues or development of disease the pre-existing murmur may mask.

**IMAGES**



The information and recommendations provided are based on the images presented by the referring veterinarian. No evaluation can be communicated regarding pathology that was not visible in the image/video clips provided.

Thank you for this referral. This report was generated using transcription software, and minor dictation errors may be present. If the clinical or image interpretation does not parallel your findings or if I can be of any further assistance, please contact me.

Maggie Machen Lamy, DVM  
Diplomate of the American College of Veterinary Internal Medicine (Cardiology)  
info@sonopath.com

Echocardiogram performed by: Pamela Harrigan, RDCS  
Pet Animal Ultrasound Service (4paus.com)